

Case report

Dynamic splinting for paediatric contracture reduction of the upper limb

Melissa Menzes* and F Buck Willis†

*Dell Children's Medical Center of Central Texas, Austin, TX, USA; †University of Phoenix: Axia College, Phoenix, AZ, USA

Correspondence: F Buck Willis, Dynasplint Systems Clinical Research, PO Box 1735, San Marcos, TX 78667, USA. Email: BuckPhD@yahoo.com

Abstract

Background. This report is based on a case of 'shaken baby syndrome,' and clinical manifestations of this injury often include hypertonicity, spasticity and joint contracture. Shaken baby syndrome affects over 1 million children and resembles symptoms of traumatic brain injury.

Methods. The patient was a five-year-old boy who had suffered a traumatic brain injury with right spastic hemiplegia. Over the course of treatment, multiple modalities were used to manage his tone, spasticity and to reduce wrist and elbow contractures, which included Botox® (Allergan Co., Irvine, CA, USA), manual therapy and dynamic splinting as home therapy. The main outcome measured was change in maximal range of motion(s) (ROMs) in the elbow and wrist.

Results. After dynamic splinting was initiated, the child's passive ROM increased by 65° in wrist extension and 45° in elbow extension. Ulnar deviation progressed by 15–30°.

Conclusion. Dynamic splinting contributed over 900 hours of end-range, home therapy for wrist extension and 700 hours in end-range home therapy for elbow extension. It is hypothesized that this prolonged duration of passive stretching at the end-range is responsible for the substantial gains in ROM.

Keywords: Brain injury, Dynasplint, home therapy

Background

More than 1.4 million children are physically abused in the USA annually, and approximately 160,000 of these children suffer lifelong and/or life-threatening injuries as a result of abuse such as 'shaken baby syndrome'.¹ Children who have suffered traumatic brain injuries (TBI) from this abuse exhibit dyskinesia, as seen in severe cerebral palsy (CP) cases. Dyskinesia is characterized by spastic movement patterns, abnormal regulation of tone, abnormal postural control and coordination deficits. Current treatments for spastic hemiplegia in paediatric patients include occupational therapy (with casting² or splinting^{3–5}), and pharmaceutical treatments such as Botox®^{6–8} or baclofen therapy⁹ and/or surgical intervention.¹⁰

Therapeutic extension movement training has been shown to benefit children with spastic hemiparesis.⁶ In this treatment, children move towards a stationary ball or a moving ball while extending the symptomatic or asymptomatic limb to intercept the ball. Kinematic aim training has increased motor speed and function, particularly when combined with initial Botox® treatments.¹¹ The 'Aim Training' was specifically designed to

test improvement in hand and elbow coordination after Botox® treatments to manage tone. Similar protocols have also shown the benefit of children's ability to participate in more intensive therapeutic protocols (increased frequency, intensity and/or time in training), which have achieved decreased tone and increased active range of motion (ROM) for enhanced motor skills.^{7,12}

Botox® injections have been shown to effectively reduce hypertonicity, but without effective concurrent therapies (including home therapy protocols) tone will be expected to return after 5–6 months.⁶ A recent pilot study of CP patients with spastic hemiplegia showed that there was a significant difference in the Goal Attainment Score⁸ following a regimented, programme of home therapy, which included a training log. However, no difference was seen in the Quality of Upper Extremity Skills Test⁸ because incremental changes in home therapy may also be needed for the patient to acquire higher skills or achieve greater ROM.

Multifaceted programmes utilizing different modalities are currently considered the best for treatment of hypertonia in children.¹⁰ This may include pharmaceutical intervention combined with effective, focused therapeutic modalities and a regimented home therapy

programme.⁴ Casting and splinting have been used by hand therapists for many years.⁴ Dynamic splinting allows absorption of spastic wrist contraction while allowing the tone to be managed afterwards.¹³⁻²¹

Dynasplint systems have shown effective use in contracture reduction and tone management in the upper extremity of patients suffering neural pathologies such as TBI, stroke and spinal injury^{13,14} (Dynasplint Systems, Inc., Severna park, MD, USA). A Dynasplint uses low-load, prolonged-duration stretch to achieve increased Total End Range Time (TERT). Using this equipment as nightly 'home therapy' while the patient sleeps or rests allows the patient to achieve an additional 42–56 hours at end-range training each week, which contributes to contracture reduction and tone/spasticity management.¹³⁻¹⁶ The purpose of this report was to describe the benefits in contracture reduction for this paediatric patient.

Case presentation

This report involved a five-year-old, Hispanic boy who was a victim of 'shaken baby syndrome' resulting in a traumatic brain injury with right spastic hemiplegia. He was non-ambulatory, dependent for all activities of daily living, and visually impaired. He displayed severe wrist flexion contracture and severe elbow flexion contracture. Treatment history included multidisciplinary, outpatient therapies for three years post-injury. Therapies have included soft and thermoplastic splinting, botulinum toxin (type A or Botox[®]) and phenol injections. The patient was referred to a Dynasplint specialist (who was an occupational therapist), following assessment at a children's spasticity clinic. The primary goals of treatment were tone management, contracture reduction of his right wrist and elbow, and increased tolerance in ROM movement.

A wrist extension Dynasplint system was prescribed for this patient initially. After success was seen with that unit, an elbow extension Dynasplint was prescribed later (Figure 1). The patient's caregiver and treating occupational therapist were given instructions for use of the neurological Dynasplint system and its protocols by the Dynasplint specialist during the initial and follow-up visits. The initial visit included customized fitting of the

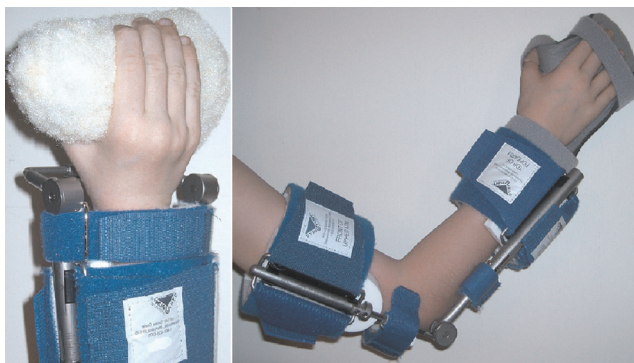

Figure 1 Paediatric wrist extension Dynasplint and elbow extension Dynasplint

Dynasplint with each patient, training (the child's parent) on donning and doffing each of the unique devices, wear and care instructions, instruction on recommended calibration changes (based on patient tolerance) and description of possible side-effects.

The normal, passive ROM in wrist extension is +80° (past neutral) and this patient's initial passive ROM, wrist extension was –80° with resting position of –100° which showed his severe wrist flexion contracture. All measurements were taken with a calibrated goniometer with tendons action of the fingers for consistency. The patient's initial ulnar deviation ranged between 45 and 60°. Children normally have full elbow extension (0° from neutral) but this child's initial, maximal passive elbow extension was –120°, with a resting position of –150° (Table 1).

The low-load tension settings of the Dynasplint were as follows: initial wrist extension tension was #3 = 0.3 ft lbs of torque and final wrist extension tension was #4 = 0.4 ft lbs. Initial tension of elbow extension was #1 = 0.1 ft lbs and final elbow extension tension was #2 = 0.2 ft lbs of torque. The goal for home therapy use was six-to-eight hours of nightly wear while sleeping in both Dynasplint units, but in this case the modalities were worn only 4–6 hours, intermittently through the day. Therapeutic modalities utilized in this case included the following: neurodevelopmental and sensory integrative therapies, therapeutic exercise, functional training, pain management and ROM. The primary care-giver also performed daily stretching as tolerated, approximately once daily for 30 minutes.

Results

After a multifaceted program with home therapy in the Dynasplint systems, this patient showed significant progress with contracture reduction in the affected upper extremity. The patient's maximal, passive wrist extension increased 65° and maximal, passive elbow extension increased 45°, (passive ROM) (see Table 1). The resting position of his wrist and elbow also increased 60° and 25°, respectively. The patient's ulnar deviation also progressed by 15–30°. The wrist extension Dynasplint was used for six months in this report and the elbow extension Dynasplint was used secondarily for four months (Figure 2). Increasing the passive ROM was beneficial for this patient's mother in hygiene and clothing of the child.

Discussion

In this patient's case, there were several variables that may have impacted his progress. These included temporarily discontinued attendance in therapy and Dynasplint wear for one month after surgical intervention of a G-tube, which was required due to an unrelated illness. Patient's overall attendance with outpatient occupational therapy was less than optimal with only 7 of 13 scheduled visits due to transportation issues. Three of the seven visits were primarily used for fitting the Dynasplints. In the other therapy visits, patient indicators of pain, fatigue or

Table 1 Changes in passive range of motion

	Wrist extension	Resting position	Ulnar deviation	Elbow extension	Resting position
Initial	-80°	-100°	45-60°	-120°	-150°
Final	-15°	-40°	30°	-75°	-125°

frustration were limiting factors with regard to the effectiveness of treatment procedures.

Increased pain following postsurgical G-tube insertion and risk of pulling out the G-tube, forced the care-giver to deviate from the prescribed usage of the Dynasplint systems (wear of the unit for 6-8 hours continuously overnight). Tension changes were rarely tolerated by the patient and the focus was on wear for prolonged, passive stretching. Despite these limitations and disruptions, the patient's changes in ROM were substantial. After goals are acquired, use of Dynasplint systems is commonly continued in neural patients to maintain the contracture reduction.

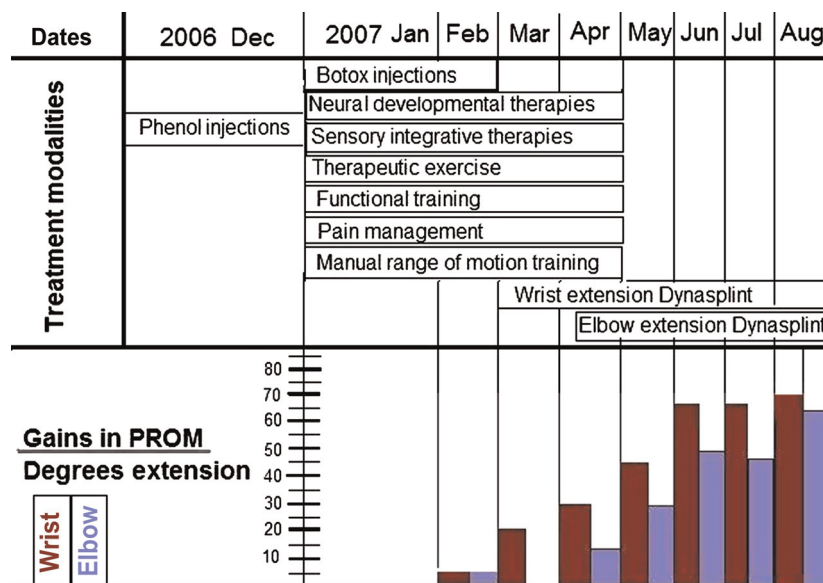
ROM exercises are important to reduce contractures occurring secondarily to spasticity and hypertonicity, thus helping maintain mobility of joints and soft tissue. The principle of low-load, prolonged-duration stretching combined with increased TERT promotes contracture reduction by the elongation of connective tissue.¹⁴⁻²² The prescribed schedule of nightly wear (while sleeping) can achieve over 200 hours of TERT each month. This child saw benefits from only wearing the Dynasplints for 4-6 hours intermittently throughout the day.

The multifaceted modalities used to treat this child's spastic hemiplegia were effective with Botox[®] preceding the therapeutic protocols described and with Dynasplint as home therapy. Using the Dynasplint systems for the home programme is an important option for victims of shaken baby syndrome and potentially any brain injury patient who often face challenges with therapy attendance and home programme carryover.

This was the first report on using Dynasplint systems for a paediatric patient with upper extremity contracture. Other studies have been published on treating upper extremity contracture in adult patients with similar Dynasplint systems. A controlled pilot study by Lai *et al.*¹⁸ showed that stroke patients treated with the elbow Dynasplint, plus standardized hand therapy and Botox[®] (experimental category) showed a 33.5% improvement in maximal elbow extension versus control patients treated only with hand therapy and Botox[®] gained only 18.7% in elbow extension. Kimbler and Willis¹⁵ reported on a patient with spinal cord injury, and after using the supination, forearm Dynasplint system the patient regained over 40° supination in each arm, allowing him to be discharged from the rehabilitation hospital. Orthopaedic studies have shown similar efficacy with use of the Dynasplint systems for contracture of the shoulder,¹⁹ forearm¹⁶ and for treating carpal tunnel syndrome.²⁰⁻²²

An experiment by Usuba *et al.* compared different protocols for passive stretching in randomized, controlled animal trials on contracture reduction, high versus low torque and duration of passive stretching, short versus prolonged. They found that the combination of low-torque stretching with prolonged durations delivered the best outcome.²³ Separate, controlled trials of Dynasplint systems described in this case report should be completed so that empirical efficacy can be measured for treating children with upper-extremity contracture secondary to hypertonicity.

The changes in Dynasplint tension were minimal, which supports the premise that prolonged duration of

**Figure 2** Sequence of treatments and results. PROM, passive range of motion

passive end-range stretching (for over 900 hours in this case) was integral to the contracture reduction.

Consent

Written informed consent was obtained from the patient's mother for publication of this case report and any accompanying images.

Acknowledgements: We thank the helpful staff at the Dell Children's Hospital, particularly Dr Brad Fullerton MD and Kitty Burton, RN from the children's spasticity clinic. We dedicate this case report in memory of Paul Molanphy, PT who was also involved in the care of this patient and development of the study.

Competing interests: This case was free of extramural funding. Mrs Menzes, OT has no conflict of interest and received no funding or earnings for this manuscript. Dr Willis is employed by the parent company of Dynasplint Systems but will not receive any funding, earnings or compensation from this manuscript. No other potential financial conflict of interest is present.

Accepted: 12 September 2011

References

- 1 Sirotnak AP, Grigsby T, Krugman RD. Physical abuse of Children. *Pediatr Rev* 2004;25:264-77
- 2 Carlson MG, Athwal GS, Bueno RA. Treatment of the wrist and hand in cerebral palsy. *J Hand Surg [Am]* 2006;31:483-90
- 3 Buonaguro V, Scelsa B, Curci D, Monforte S, Iuorno T, Motta F. Epilepsy and intrathecal baclofen therapy in children with cerebral palsy. *Pediatr Neurol* 2005;33:110-3
- 4 Blair E, Ballantyne J, Horsman S, Chauvel P. A study of a dynamic proximal stability splint in the management of children with cerebral palsy. *Dev Med Child Neurol* 1995;37:544-54
- 5 Chan RK. Splinting for peripheral nerve injury in upper limb. *Hand Surg* 2002;7:251-9
- 6 Ricken AX, Savelsbergh GJ, Bennett SJ. External timing constraints facilitate performance of everyday interceptive actions in children with spastic hemiparetic cerebral palsy. *Neurosci Lett* 2006;410:187-92
- 7 Verrotti A, Greco R, Spalice A, Chiarelli F, Iannetti P. Pharmacotherapy of spasticity in children with cerebral palsy. *Pediatr Neurol* 2006;34:1-6
- 8 Novak I, Cusick A, Lowe K. A pilot study on the impact of occupational therapy home programming for young children with cerebral palsy. *Am J Occup Ther* 2007;61:463-8
- 9 Hayden RJ, Jebson PJ. Wrist arthrodesis. *Hand Clin* 2005;21:631-40
- 10 Sanger TD. Hypertonia in children: how and when to treat. *Curr Treat Options Neurol* 2005;7:427-39
- 11 Rameckers EA, Speth LA, Duysens J, Vles JS, Smits-Engelsman BC. Kinematic aiming task: measuring functional changes in hand and arm movements after botulinum toxin-A injections in children with spastic hemiplegia. *Am J Phys Med Rehabil* 2007;86:538-47
- 12 Speth LA, Leffers P, Janssen-Potten YJ, Vles JS. Botulinum toxin A and upper limb functional skills in hemiparetic cerebral palsy: a randomized trial in children receiving intensive therapy. *Dev Med Child Neurol* 2005;47:468-73
- 13 Nuismer BA, Ekes AM, Holm MB. The use of low-load prolonged stretch devices in rehabilitation programs in the Pacific northwest. *Am J Occup Ther* 1997;51:538-43
- 14 Willis B. Post-TBI gait rehabilitation. *Appl Neurol* 2007;3:25-26
- 15 Kimbler TS, Willis FB. Dynamic splinting for pronation contracture following a spinal cord injury. *Hand Ther* 2010;15:20-2
- 16 Berner SH, Willis FB. Dynamic splinting in wrist extension following distal radius fractures. *J Orthop Surg Res* 2010;5:53
- 17 Lundequam P, Willis FB. Dynamic splinting as home therapy for toe walking: a case report. *Cases J* 2009;2:188
- 18 Lai JM, Francisco GE, Willis FB. Dynamic splinting on range of motion and spasticity after treatment with Botulinum Toxin-A: a randomized, controlled pilot study. *Adv Ther* 2009;26:241-8
- 19 Gaspar PD, Willis FB. Adhesive capsulitis and dynamic splinting: a controlled, cohort study. *BMC Musculoskelet Disord* 2009;10:111
- 20 Berner and Willis. Treatment of carpal tunnel syndrome with Dynasplint: a randomized, controlled trial. *J Med* 2008;1:1-5
- 21 Berner SH, Willis FB, Shanmugan R. Pain from carpal tunnel syndrome reduced with dynamic splinting: a retrospective study of 156 patients. *J Clin Med Res* 2009;1:22-5
- 22 Wallen M, O'Flaherty SJ, Waugh MC. Functional outcomes of intramuscular botulinum toxin type a and occupational therapy in the upper limbs of children with cerebral palsy: a randomized controlled trial. *Arch Phys Med Rehabil* 2007;88:1-10
- 23 Usuba M, Akai M, Shirasaki Y, Miyakawa S. Experimental joint contracture correction with low torque-long duration repeated stretching. *Clin Orthop Relat Res* 2007;456:70-8